



# Handbook for Children with Renal Tumors

Winter 2018

from the  
Cancer Committee  
of the  
American Pediatric Surgical Association

©2018, American Pediatric Surgical Association

## **CONTRIBUTORS**

Todd E. Heaton, MD, MPH  
Assistant Member, Pediatric Surgery  
Memorial Sloan Kettering Cancer Center  
New York, NY

Jaimie D. Nathan, MD  
Associate Professor  
Cincinnati Children's Hospital Medical Center  
Cincinnati, OH

John J. Doski, MD  
Pediatric General and Thoracic Surgery San  
Antonio Pediatric Surgery Associates San  
Antonio, TX

Peter F. Ehrlich, MD  
Professor  
University of Michigan CS Mott Children's Hospital  
Ann Arbor, MI

## **NOTICE**

The authors, editors, and APSA disclaim any liability, loss, injury or damage incurred as a consequence, directly or indirectly, of the use or application of any of the contents of this volume. While authors and editors have made every effort to create guidelines that should be helpful, it is impossible to create a text that covers every clinical situation that may arise in regards to either diagnosis and/or treatment. Authors and editors cannot be held responsible for any typographic or other errors in the printing of this text. Any dosages or instructions in this text that are questioned should be cross referenced with other sources.

Attending physicians, residents, fellows, students and providers using this handbook in the treatment of pediatric patients should recognize that this text is not meant to be a replacement for discourse or consultations with the attending and consulting staff. Management strategies and styles discussed within this text are neither binding nor definitive and should not be treated as a collection of protocols.

## **TABLE OF CONTENTS**

1. [Introduction](#)
2. [One-Minute Review](#)
3. [Staging - Wilms'](#)
4. [Staging - Renal Cell Carcinoma](#)
5. [Operative Procedures Primary Tumor](#)
6. [Lymph Node Documentation](#)
7. [Tumor Biopsy](#)
8. [Tumor Spillage](#)
9. [Renal Vein/Inferior Vena Cava](#)
10. [Surgical Management of Metastases](#)
11. [Initially Unresectable Tumors](#)
12. [Operative Procedures for Bilateral Tumors](#)

## **INTRODUCTION**

This handbook provides you with the current surgical management of Renal Tumors as of 2018. It is based on current literature and accepted practice, and is managed and updated by the APSA Cancer Committee. It is designed to consolidate the most current and up to date material you need to know when treating your patient. *Please note as new Children Oncology Group Studies are developed it is always good to go directly to the study protocol to ensure the surgical guidelines have not changed.* Renal Tumor treatment is centered on risk stratification according to histopathology, surgical stage, biologic markers such as loss of heterozygosity, and response to treatment.

This handbook begins with A One Minute Review which is designed for use immediately before an operation and includes abbreviated staging, risk stratification, surgery guidelines, and tissue handling. There follows more descriptive sections for in depth staging and surgical management for all stages of renal tumors, including bilateral (stage V).

Much of this knowledge has been discovered by strong clinical trials as the National Wilms' Tumor Study Group (NWTS I-V) and Renal Tumor Protocols with the Children's Oncology Group. Enrollment on open biologic and clinical trials with the Children's Oncology Group is strongly encouraged.

Surgery Study members are listed below, and should be contacted for questions. Any and all suggestions for improvement are welcome.

### **APSA Pediatric Surgical Contacts for Questions:**

Peter Ehrlich, MD	(734) 763-2072	pehrlich@med.umich.edu
Jennifer Aldrink, MD	(614) 722-0440	jennifer.aldrink@nationwidechildrens.org
Nicholas Cost, MD	(720) 777-5084	nicholas.cost@childrenscolorado.org
Richard Glick, MD	(718) 470-3636	rglick@northwell.edu
Kenneth Gow, MD	(206) 987-3241	kenneth.gow@seattlechildrens.org
Thomas Hamilton, MD	(617) 355-3038	thomas.hamilton@childrens.harvard.edu
Marcus Malek, MD	(412) 692-8735	marcus.malek@chp.edu
Jaimie Nathan, MD	(513) 636-4371	Jaimie.nathan@cchmc.org
Elisabeth Tracy, MD	(919) 681-5077	elisabeth.tracy@duke.edu

## RENAL TUMORS – ONE-MINUTE REVIEW

### STAGES

#### Children Oncology Group Wilms Tumor Staging

##### Stage I

The tumor is limited to the kidney and has been completely resected  
The tumor was not ruptured or biopsied prior to removal.  
No penetration of the renal capsule or involvement of renal sinus vessels.

##### Stage II

The tumor extends beyond the capsule of the kidney but was completely resected with no evidence of tumor at or beyond the margins of resection.  
There is penetration of the renal capsule or  
There is invasion of the renal sinus vessels

##### Stage III

Gross or microscopic residual tumor remains postoperatively including:  
inoperable tumor, positive surgical margins, tumor spillage surfaces, regional lymph-node metastases, positive peritoneal cytology or transected tumor thrombus  
The tumor was ruptured or biopsied prior to removal.

##### Stage IV

Haematogenous metastases or lymph-node metastases outside the abdomen (eg, lung, liver, bone, brain).

##### Stage V disease

Bilateral renal involvement is present at diagnosis and each side may be considered to have a stage.

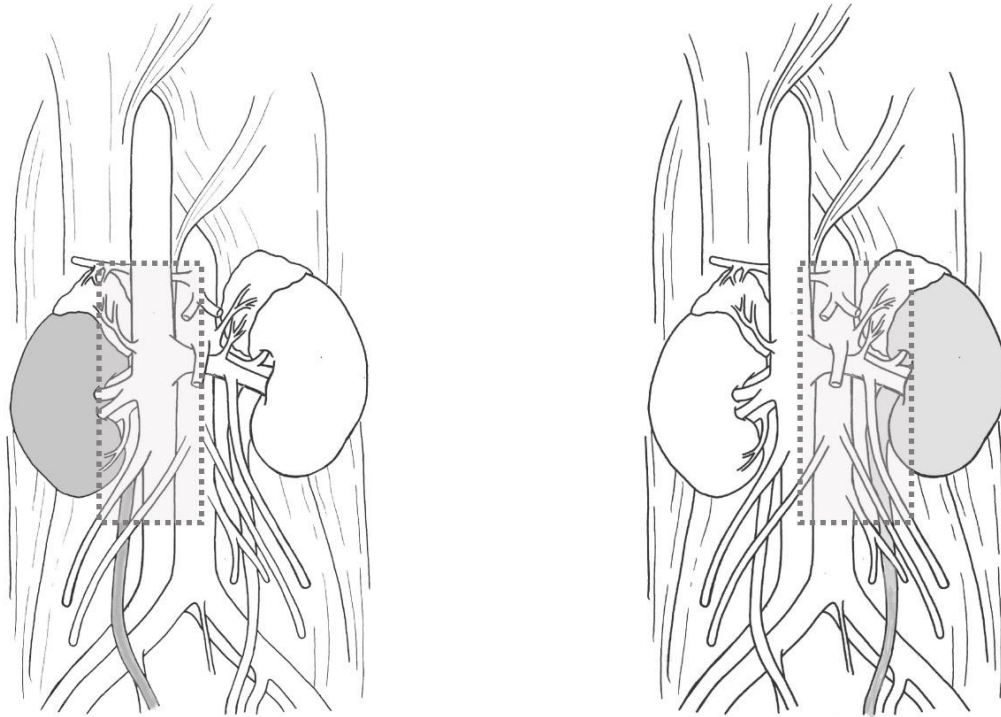
### SURGICAL PRINCIPLES

#### Stages I-IV

Complete abdominal exploration. Unilateral radical nephrectomy with lymph node sampling via transperitoneal incision. Avoid rupture or spillage by use of adequate incision. Flank incision should not be utilized. Palpate renal vein and IVC for extension. Visualization and palpation of contralateral kidney not necessary if imaging normal. Ureter is ligated and divided as low as conveniently possible. Titanium clips used only to identify residual tumor, margins of dissection, and suspicious areas. **DO NOT BIOPSY TUMOR In VIVO.**

Lymph node dissection should include renal hilar, paraaortic and/or paracaval nodes, as well as any suspicious nodes, with a goal to obtain **5 or more lymph nodes** and document where there were taken. Lymph node sampling must be pursued and established to confirm node negative status for treatment. For tumors believed unresectable at initial operation, adequate biopsy should be performed.

**Figure 1.** In each drawing, the shaded kidney indicates the side of the radical nephrectomy and the box indicates the extent of the nodal dissection for Wilms tumor. Please note that the aortocaval nodes are included in the recommended sampling regardless of the side of the lesion.



#### Stage V

NO initial biopsy needed in most cases. Although it would be very unlikely to have a misdiagnosis in patients with bilateral lesions, when there is an unusual clinical situation that may suggest a diagnosis other than Wilms tumor, such as age > 10 years or atypical imaging features obtaining a tissue diagnosis before starting therapy should be considered.

Start with upfront 3 drug chemotherapy, vincristine, actinomycin D, and doxorubicin. Reevaluate at 6 wks for possible biopsy if <50% reduction in size, If biopsy is performed it should be done on both kidney due to 20% discordant rate (or resect if resectable), vs continued chemotherapy with operation at 12 weeks, nephrectomy if kidney not salvageable. Sparing of normal renal parenchyma is paramount.

#### Contraindications to primary nephrectomy

There are several current guidelines for an unresectable tumor:

(1) A tumor with extension of tumor thrombus into the IVC that extends to the level of the retro-hepatic cava should be seriously considered as an unresectable tumor and tumor that extends above the level of the hepatic veins is a definite contraindication.

(2) When the tumor involves contiguous structures whereby the only means of removing the kidney and tumor requires removal of the other structures (e.g., spleen, pancreas, colon, but excluding the adrenal gland and diaphragm).

(3) Bilateral tumors.

(4) Tumor in a solitary kidney.

(5) If there is pulmonary compromise due to extensive pulmonary metastases

#### TISSUE HANDLING

Do Not Bivalve or otherwise disrupt capsule in OR. **Send intact specimen FRESH. Label sites of all lymph nodes sampled.**

## STAGING

**Renal tumors receive both a local abdominal tumor stage and a disease stage. These may be the same but it is not unusual that a child may have a local stage I and II tumor but also have pulmonary metastasis with a disease stage IV. Please note the treatment for these children is very different than children with local stage III and disease stage IV**

**Stage I** - Tumor limited to kidney, completely resected. The renal capsule is intact. The tumor was not ruptured or biopsied prior to removal. The vessels of the renal sinus are not involved. There is no evidence of tumor at or beyond the margins of resection. NOTE: For a tumor to be considered Stage I, regional lymph nodes must be examined microscopically. Failure to sample lymph nodes may result in incorrect staging, increase recurrence rates and would exclude the patient from being treated by surgery alone (Please note that current Cog studies is looking at the specific location and number of lymph nodes sampled and is recommending that 5 be sampled if possible)

**Stage II** - The tumor is completely resected and there is no evidence of tumor at or beyond the margins of resection. The tumor extends beyond kidney, as is evidenced by any one of the following criteria:

- There is regional extension of the tumor (i.e. penetration of the renal capsule, or extensive invasion of the soft tissue of the renal sinus, as discussed below)
- Blood vessels within the nephrectomy specimen outside the renal parenchyma, including those of the renal sinus, contain tumor.

Note: Rupture or spillage confined to the flank, including biopsy of the tumor, is no longer Stage II. It is Stage III.

**Stage III** - Residual non-hematogenous tumor present following surgery, that is confined to abdomen. Any one of the following may occur:

- Lymph nodes within the abdomen or pelvis are involved by tumor. (Lymph node involvement in the thorax, or other extra-abdominal sites is a criterion for stage IV),
- The tumor has penetrated through the peritoneal surface,
- Tumor implants are found on the peritoneal surface,
- Gross or microscopic tumor remains post-operatively (e.g., tumor cells are found at the margin of surgical resection on microscopic examination),
- The tumor is not completely resected because of local infiltration into vital structures,
- Tumor spillage occurring either before or during surgery,
- The tumor was biopsied (whether, tru-cut, open or fine needle aspiration) before removal,
- Tumor is removed in more than one piece (e.g. tumor cells are found in a separately excised adrenal gland; a tumor thrombus within the renal vein is removed separately from the nephrectomy specimen).

**Stage IV** - Hematogenous metastases (lung, liver, bone, brain, etc.), or lymph node metastases outside the abdomino-pelvic region are present. The presence of tumor within the adrenal gland is not interpreted as metastasis and staging depends on all other staging parameters present. Local staging of the renal tumor by the criteria above is necessary to guide local therapy.



**Stage V** - Bilateral renal involvement by tumor is present at diagnosis. An attempt should be made to stage each side according to the above criteria on the basis of the extent of disease

**Staging of Renal Cell Carcinoma by the TNM system:**

**T--Primary Tumor**

- TX Primary tumor cannot be assessed
- T0 No evidence of primary tumor
- T1 Tumor 7.0 cm or less in greatest dimension, limited to the kidney
- T2 Tumor more than 7.0 cm in greatest dimension, limited to the kidney
- T3 Tumor extends into major veins or invades adrenal gland or perinephric tissues but not beyond Gerota's fascia
- T3a Tumor invades adrenal gland or perinephric tissues but not beyond Gerota's fascia
- T3b Tumor grossly extends into renal vein(s) or vena cava below diaphragm
- T3c Tumor grossly extends into vena cava above diaphragm
- T4 Tumor invades beyond Gerota's fascia

**N--Regional Lymph Nodes** (Hilar, abdominal para-aortic, and paracaval nodes. Laterality has no effect):

- NX Regional lymph nodes cannot be assessed
- N0 No regional lymph node metastasis
- N1 Metastasis in a single regional lymph node
- N2 Metastasis in more than one regional lymph Node

**M--Distant Metastasis**

- MX Distant metastasis cannot be Assessed
- M0 No distant metastasis
- M1 Distant metastasis

**Stage Grouping for Renal Cell Carcinoma:**

Stage I	T1	N0	M0
Stage II	T2	N0	M0
Stage III	T1	N1	M0
	T2	N1	M0
	T3	N0 or N1	M0
Stage IV	T4	N0, N1	M0
	Any T	N2	M0
	Any T	Any N	M1

## **Operative Procedure for Primary Tumor**

The essential tasks that are required of the surgeon, irrespective of when the WT resection occurs, are: (1) safe resection of the tumor; (2) accurate staging of the tumor; (3) avoidance of complications that 'upstage' the tumor (rupture or unnecessary biopsy); and (4) accurate documentation of the operative findings and details of the procedure in the operative notes. Tumor spill, failure to biopsy lymph nodes (for both unilateral and bilateral tumors), incomplete tumor removal, failure to assess for extrarenal tumor extension, and operative complications will adversely impact patient survival.

Prior to operation, coagulation studies should be obtained because acquired von Willebrand disease (vWD) has been reported in WT and other malignancies. A single prospective study of 50 WT patients found the incidence of acquired vWD was 8%.<sup>94</sup> However, the true incidence and prevalence is unknown. Historically, when coagulation abnormalities have been identified, they were felt to be clinically insignificant. However, reports of profuse intraoperative bleeding (despite normalization of FVIII, vWF activity, and antigen level prior to operation) that only stopped after ligation of the renal vessels have contradicted this assumption. Once the renal vessels were ligated, all abnormal bleeding stopped. The mechanism of acquired vWD in WT is unknown. In all cases where bleeding occurred, the child had a prolonged PT and PTT. Correction of these abnormalities is important. The observation that bleeding stopped when the renal vessels were ligated suggests that preoperative embolization should be considered as a management strategy.

### **Primary Nephrectomy, Stage I-IV**

A generous transabdominal or thoracoabdominal incision is recommended for adequate exposure. Flank or retroperitoneal resection is contraindicated due to an increased rate of rupture. Complete exploration of the abdomen should be performed. A radical nephrectomy is performed with the ureter divided as distally as possible. Routine exploration of the contralateral kidney is not necessary if technically adequate imaging does not suggest a bilateral process. (For surgical guidelines for bilateral tumors see next section) If the initial imaging studies are suggestive of a lesion on the contralateral kidney, the contralateral kidney should be formally explored to rule out bilateral involvement prior to nephrectomy since the diagnosis of bilateral disease is a contraindication to upfront nephrectomy. To do this exploration adequately, the colon and its mesentery should be mobilized from the anterior surface of the contralateral kidney, Gerota's fascia incised, and the kidney turned forward to palpate and visualize both its anterior and posterior surfaces. Any areas suggestive of bilateral involvement should be biopsied. See procedures for tumor biopsy below.

To expose the primary tumor, the lateral peritoneal reflection is then opened, and the colon is reflected medially. A plane is established outside of Gerota's fascia by sharp and blunt dissection. Before mobilizing the primary tumor, an attempt should be made to dissect, expose and ligate the renal vessels. **Preliminary ligation should not be pursued if technically difficult or dangerous due to tumor size or extensive lymph node involvement.** The adrenal gland may be left in place if it is not abutting the tumor; but, if the mass arises in the upper pole of the kidney, the adrenal gland should be removed with the neoplasm. The ureter is ligated and divided as low as conveniently possible, but

it is not necessary to remove the entire ureter. The tumor and the uninvolved portion of the kidney are mobilized and removed intact. Any enlarged or suspicious lymph nodes should be included with the specimen.

The use of titanium clips is strongly recommended to identify gross residual tumor. Clips should not be used for hemostasis and those placed for residual tumor identification or radiation therapy portals should be limited to the minimum number necessary. Metallic clips can interfere with the CT scan. Clips are best applied by placing a non-absorbable suture in the structure to be marked, and attaching the clip to the suture. In general four small clips should be sufficient to delineate the margins of the tumor.

Any suspicious areas that could represent metastases should be biopsied, the site(s) identified with small titanium clips so that the locations can be determined later by imaging.

The involved areas should be drawn on the diagram in the surgical checklist. The specimen should be specifically identified as to the site from which it was removed.

### **Contiguous Organs**

Wilms' tumors are frequently adherent to adjacent organs. In the majority of cases, there is not frank invasion by the tumor. Radical en bloc resection, e.g. partial hepatectomy is not generally warranted. Extensive resection including multiple organs, e.g. spleen, pancreas, and colon, is **NOT** advised as this is associated with an increased frequency of complications. If removal of a small section of diaphragm, psoas muscle, or tip of the pancreas allows the tumor to be removed intact, then proceed.

### **Partial Nephrectomy (for Stages I-IV)**

Partial nephrectomy is **NOT** indicated in the routine patient with unilateral Wilms' tumor. The exception is the child with a Wilms' tumor-predisposing syndrome (eg. WAGR, Beckwith Wiedemann, Denys Drash etc) who although presenting with a unilateral tumor is predisposed to the subsequent development of contralateral disease. Hence, such children need to be managed with neoadjuvant chemotherapy and a renal sparing approach as for bilateral tumors.

### **Lymph Node Sampling**

The presence or absence of disease in hilar and regional lymph nodes is an extremely important factor in accurate staging and appropriate treatment. Achieving adequate lymph node sampling with nephrectomy is critical, so removing nodes from the renal hilum, the paracaval or paraaortic areas, and the aortocaval area must be done for accurate staging. This is especially important for those patients being considered for surgical resection alone. Involved or suspicious lymph nodes should be excised. Label the nodes carefully for separate microscopic examination. All lymph nodes removed should be identified on the surgical check list and the accompanying diagram. Please note that current Cog studies is looking at the specific location and number of lymph nodes sampled and is recommending that 5 be sampled if possible

## Assignment of Surgical Stage

The surgeon should assign a "local-regional stage" to the tumor based solely on the operative findings and findings on pathologic examination. Knowledge of distant metastases does not influence local surgical staging. For example, the patient would be evaluated as "surgical stage III" if there were obviously positive lymph nodes even if it were known that pulmonary metastases were also present.

## Tumor Biopsy

Pre-nephrectomy tumor biopsies are contraindicated. Studies have shown a higher risk of recurrence in patients who had tumor spills or ruptures irrespective of the cause or extent of the soiling. These events result in an increased risk of local recurrence and increased adjuvant therapy with those attendant risks. Tumor biopsy prior to nephrectomy is considered local spill which results in up-staging children to stage III, requiring additional chemotherapy (doxorubicin) and 10cGy flank radiation.

**Preoperative and intraoperative biopsies are therefore contraindicated and should only be performed when a tumor is deemed unresectable.** Either open or multiple core biopsied are recommended as needle biopsy cannot distinguish between a tumor and a rest nor can it diagnose diffuse anaplasia. Open biopsies and multiple cores are also better for obtaining the biological samples needed for staging

## Tumor Spillage

It is important for accurate staging to document the extent of any peritoneal soilage by tumor since this will determine the extent of radiation therapy. The peritoneum is considered "soiled" if there has been a biopsy (either pre operative or intra operative) of a tumor that is removed at initial surgery, if there has been preoperative rupture, if there is intraoperative tumor spill, or if the tumor has been removed in more than one piece. Local spills are defined as those limited to the renal fossa.

Wilms tumor can spill or rupture before and during surgery. This results in soiling of the peritoneal cavity and mandates Stage III therapy. The peritoneum shall be considered "soiled" if there has been:

1. ANY biopsy (either preoperative or intraoperative) in a tumor that is subsequently removed,
2. Preoperative rupture,
3. A tumor spill during surgery, or
4. Separate tumor; nodules on the peritoneal or serosal surfaces are considered a preoperative tumor rupture.

Tumors and adherent tissues that are removed en bloc should produce no tumor spill. However, tumor tissue may be cut across during removal of adherent structures or during removal of lymph nodes. Tumors that are removed in more than one piece, the neoplastic tissue having been cut across in the process, shall be considered to have spilled. Spill would also occur if the surgeon transected the renal vein or ureter at the site of tumor extension. Rupture refers to either the spontaneous or post-traumatic rupture of the tumor preoperatively with the result that tumor cells are disseminated

throughout the peritoneal cavity. Bloody peritoneal fluid **MAY BE** considered a sign of rupture. A large amount of blood is unusual and capsular disruption is usually found and must be documented. When a hematoma is present, it is assumed that tumor cells will spread with the blood. Both of these situations are classified as preoperative rupture.

Tumor may penetrate the kidney capsule, and the overlying peritoneum, the raw neoplastic tissue surface being in free communication with the peritoneal cavity. If this is found at surgery, it is a sign of preoperative rupture. Peritoneal fluid can be sampled for cytology. However detecting actual malignant cells can be difficult and frequent false positives have been reported. If malignant cells are found, it is suggested that the slides be forwarded to central pathology so that they can be reviewed in conjunction with the treating institution. If cytological analysis of the peritoneal fluid is positive for malignant cells, it is highly suggestive of a preoperative tumor rupture.

**All instances of soilage will be classified as Stage III and require abdominal radiation. Flank radiation is given to all Stage III patients with three exceptions (the patients meeting any of these exceptions requiring whole abdominal radiation):**

1. Preoperative tumor rupture
2. Peritoneal metastases are found at initial surgery
3. A large intraoperative tumor spill affecting areas outside the tumor bed as determined by the surgeon /treating institution. (Note that it can be difficult to determine the extent of the spill. If the surgeon feels that the spill was confined to the renal tumor bed and controlled immediately, flank RT should be given. If there is concern for more extensive tumor spill, whole abdominal RT should be given

When tumor extends into the renal vein or inferior vena cava, a precise description of the technique of removal should be given in the operative note. It must be stated in the operative report if the intravascular tumor extension was removed en bloc or if tumor was transected during the resection. It must also be clear whether the tumor thrombus has been removed completely and if there is evidence of either adherence or invasion of the vein wall, with specifics noted regarding site of remaining intravascular tumor thrombus.

### **Renal Vein/Inferior Vena Cava**

Vascular invasion of the renal vein, cava and atrium presents special surgical challenges, and, since these tumors will often respond to preoperative therapy, management requires careful consideration. Renal vein involvement has been noted in 11% of cases (most often detected at operation) and caval and atrial involvement in 5% of Wilms' tumor cases. The pre operative ultrasound and CT scan will usually identify intravascular tumor extension but the renal vein and inferior vena cava should still be palpated carefully before ligation to rule out extension of the tumor into the vein.

Tumor extension into the renal vein and proximate inferior vena cava can in most cases be removed en-bloc with the kidney. However, primary resection of tumors that extend up the inferior vena cava to the level of the hepatic veins and particularly to the atrium is associated with higher operative morbidity. In these circumstances, preoperative chemotherapy decreases the size and extent of the tumor thrombus facilitating subsequent excision.

The tumor that extends into the renal vein and cava may simply extend as a floating attachment and can then be “fished out”. Control of the renal vein and cava above and below the tumor with vessel loops is essential. Silk 2-0 stitches can then be placed on either side of the renal vein. This will help with vascular control and limit bleeding. The tumor and kidney should be completely mobilized prior to removing a vascular thrombus. For thrombus extending into the retrohepatic vena cava, mobilization of the right hemiliver will facilitate exposure. A venotomy is then created and the tumor pulled out of the vein. A foley balloon technique can also be used to pull out the tumor. The tumor should not be transected.

In other instances the tumor may be fixed to the vascular lumen. Extraction is more difficult and a larger venotomy may be required. A similar technique used for removing plaque for a carotid endarterectomy is helpful to lift the tumor off the vein wall. If after preoperative chemotherapy the tumor still extends above the hepatic veins, cardiopulmonary bypass is required to remove the intravascular extent of the tumor. The abdominal tumor is mobilized and removed first prior to administration of heparin. After placing the child on bypass the right atrium is opened and the tricuspid valve inspected. The tumor is removed from the heart above and below at the same time to prevent tumor emboli.

### **Surgical Management of Metastases**

#### **Intra-abdominal Metastases**

Any suspicious site in the abdomen or liver should be biopsied or resected (if easily removed) at exploration to determine the nature of the mass as it will affect tumor stage and therapy. If residual intra-abdominal metastatic disease remains at week 12 of chemotherapy, it should be resected only if complete resection is feasible. If complete resection is not feasible, then residual disease should be reassessed for feasibility of resection at the completion of therapy.

#### **Pulmonary Metastases**

It is strongly recommended that if there is any doubt about the nature of pulmonary nodules that these be biopsied since as many as one third of small (<1 cm) lesions may not be metastatic tumor. Note however, that stage III and IV patients will receive the same chemotherapy for the first six weeks. Only patients with residual pulmonary lesions at this time will receive whole lung radiation. Thus it is only for patients with local stage I and II tumors that it is critical to define the nature of small pulmonary lesions at diagnosis.

It is strongly recommended to biopsy residual pulmonary lesions at week six if there is any doubt about the nature of the lesions prior to committing the patient to whole lung radiation and intensification of chemotherapy. Patients will still receive intensified therapy however, even if all disease is surgically resected.

Most metastases are peripheral and superficial and can be removed thoracoscopically. For larger lesions a standard posterior lateral thoracotomy can be used.

If pulmonary nodules remain after Week 12 of chemotherapy and irradiation, they should be resected if complete resection is feasible. If complete resection is not feasible, then imaging studies should be repeated at the end of protocol therapy to reassess for feasibility of resection.

### Bone Metastases

Surgical resection of bone metastases is rarely recommended and should be considered only if it would result in removal of all known disease. Bone metastases are treated primarily with radiation therapy.

### Brain Metastases

Surgical resection of brain metastases may be considered before the initiation of chemotherapy if complete resection is feasible.

### *Management of Tumor Extension in the Ureter*

Extension of WT into the ureter is a rare event which can be difficult to detect with preoperative imaging. In NWT5-5, the incidence of ureteral extension was 2%. However, preoperative imaging detected the ureteral involvement in only 30%. Clinical findings of ureteral involvement can include gross hematuria, passage of tissue per urethra, hydronephrosis, and a urethral mass. If these findings are encountered, ureteral involvement should be suspected. Cystoscopy with a retrograde ureterogram may aid in the preoperative evaluation. When encountered or suspected, the ureter with tumor extension should be resected with clear margins.

### *Horseshoe Kidney, Single Kidney and Nonfunctioning Kidney*

Children with a tumor in a horseshoe kidney should be treated as having a unilateral tumor, not a bilateral tumor. The blood supply to horseshoe kidneys is quite variable as is the location of the ureters which should be delineated prior to operation. The side of the kidney containing the tumor, the isthmus, and the ipsilateral ureter are resected and the lymph nodes are sampled for staging. Children with a single kidney, or a situation where a tumor occurs in one kidney but the second kidney is nonfunctioning, should be managed using a renal-sparing approach with preoperative chemotherapy to facilitate preservation of renal tissue.

### **Unresectable Renal Tumors**

Tumors should be considered unresectable if:

- There is extension of tumor thrombus to the level of the hepatic veins. These patients should be considered for tumor resection when there is evidence of regression of the vena caval thrombus regardless of the degree of response of the primary tumor.
- The tumor involves contiguous structures whereby the only means of removing the kidney tumor requires removal of the other structure (e.g. spleen, pancreas, colon but excluding the adrenal gland). Note however, that Wilms' tumors are frequently adherent to adjacent organs. In the majority of cases, there is not frank invasion by the tumor and the organs can be dissected freely from the tumor. Radical en bloc resection, e.g. partial hepatectomy is not generally warranted. If however, removal of a small section of diaphragm, psoas muscle, or tip of the pancreas allows the tumor to be removed intact, this is considered safe and appropriate.

- If it is the surgeons' judgment that nephrectomy would result in significant or unnecessary morbidity/mortality, diffuse tumor spill or residual tumor.
- If there is pulmonary compromise due to extensive pulmonary metastases.

Past experience in NWTSG and SIOP has shown that pretreatment with chemotherapy almost always shrinks the tumor and renders it safely resectable, while allowing preservation of the contiguous organs. However, this method does not result in improved survival rates, and does result in the loss of important staging information. It is recommended that all patients without the contraindications previously listed undergo initial exploration to assess operability. It is only then that biopsy should be considered, if resection is not feasible. Thorough exploration of the abdomen is necessary to detect evidence of extrarenal extension of tumor. If suspicious lymph nodes or other metastatic deposits are found, these should be biopsied to document tumor involvement. Patients who are staged by imaging studies alone are at risk for understaging and overstaging. If pre-nephrectomy therapy is given, with or without a needle biopsy, the local tumor is considered stage III. Radiographic reevaluation should be performed at week six and the operative procedure shortly thereafter if sufficient tumor shrinkage has occurred. Serial imaging evaluation is helpful to assess response, but radiographic evidence of persistent disease can occasionally be misleading. Little additional tumor regression can be expected after 4 courses of chemotherapy.

### **Operative Procedure for Bilateral Tumors**

Review of NWTSG data found little meaningful staging information was obtained with exploration or biopsy unless the patient was undergoing primary tumor resection, e.g. nephrectomy or partial nephrectomy. Studies have shown a higher risk of local recurrence in patients who had tumor spills or ruptures irrespective of the cause or extent of the soiling. In COG studies, all patients with tumor spill, including biopsy, are considered Stage III. As a result, initial biopsy for bilateral tumors is NOT recommended. However, patients with favorable histology bilateral tumors who do undergo biopsy may not require radiation therapy unless there are other specific factors that warrant a designation of Stage III, such as lymph node involvement.

There are situations where the radiographic appearance of the tumor may lead to uncertainty in the diagnosis. If the treating clinician wants to obtain a tissue diagnosis before starting therapy, needle biopsies via a posterior approach to limit intraperitoneal spill are preferred. After six weeks of chemotherapy the patient will be re-imaged to determine response to chemotherapy. If there is less than 50% response to the chemotherapy, bilateral open renal biopsies are recommended. Open biopsies are recommended because they are more accurate than percutaneous needle biopsies when assessing anaplasia. The goal of the biopsy is to assess tumor histology of non-responding tumors. The histology of the biopsy will determine whether additional chemotherapy is warranted before proceeding with surgery or if a change in the chemotherapy regimen is needed.



## Partial Nephrectomy for Bilateral Tumors

It is recommended that if you do not do these operations regularly to contact one of the renal surgeons who can provide expertise and guidance

Assessment of differential renal function with a radionuclide renal scan (e.g. DMSA scan) prior to and after surgery should be considered per institutional practice. A transperitoneal incision is used. Inspect the renal hilar and periaortic area and sample lymph nodes to rule out lymphatic spread. Palpate the renal vein and IVC for evidence of tumor extension. Do not biopsy the tumor if a partial nephrectomy with margins can be performed since this is a criterion for Stage III. Avoid rupture or spillage by use of an adequate incision. Control of the renal vessels is recommended, but the surgery can be performed without hypothermia or vascular ischemia. In most children, manual compression of the kidney can be used to control bleeding during the dissection. Intra-operative US has been found to be helpful to define good surgical borders by many investigators. Use of a harmonic scalpel, bipolar or a similar device may help reduce blood loss and maintain hemostasis. Gerota's fascia is opened and the perirenal fat is dissected off the renal surface excluding the fat attached to the mass. A circumferential incision of the renal capsule around the surface of the tumor should be performed and the capsule peeled back to expose the adjacent renal parenchyma. A wedge or guillotine resection of the tumor is performed. The tumor should be excised with a 0.5 to 1 cm rim of normal parenchyma. After removal of the tumor any bleeding vessels can be suture ligated. If there is transection of the collecting system, a watertight closure with fine absorbable suture is recommended. During the mobilization of the kidney and during dissection of the tumor, care must be taken not to place traction on the renal vessels. The small vessels in these young patients are prone to intimal injury which can lead to spasm and subsequent thrombosis. Following any surgical procedure, if the specimen reveals diffuse anaplasia and there is incomplete resection, additional surgery is indicated to ensure complete resection of the tumor.

## Enucleation

Enucleation of the tumor (removal of a tumor from the surrounding tissue) may be the only option for removal of some centrally located tumors. Tumors in this location do not have adjacent renal parenchyma to allow for a partial nephrectomy as described in. These tumors often compress the renal sinus and abut against both the renal vasculature and collecting system. After chemotherapy, these tumors are often firm with a capsule around the surface of the tumor. This allows for blunt dissection with enucleation of the tumor mass. This procedure should be considered only for patients with favorable histology Wilms tumor. If anaplasia is present, enucleation is contraindicated. Clear margins are mandated for anaplastic tumors. The surgical approach for enucleation is the same as for partial nephrectomy. A transperitoneal incision is used. Inspect the renal hilar and periaortic area and sample lymph nodes to rule out lymphatic spread. Palpate the renal vein and IVC for evidence of tumor extension. Do not biopsy the tumor if a partial nephrectomy with margins can be performed since this is a criterion for Stage III. During the mobilization of the kidney and during dissection of the tumor, care must be taken not to place traction on the renal vessels. The small vessels in these young patients are prone to intimal injury which can lead to spasm and subsequent thrombosis.

## Indications for Nephrectomy with Bilateral Disease

- Bilateral Wilms' tumor: partial nephrectomy is not feasible after 12 weeks of chemotherapy.
- Unilateral Wilms' tumor at high risk for bilateral Wilms' tumor:
  - a. partial nephrectomy is not feasible after six weeks of chemotherapy and there has been less than a 50% response to chemotherapy.
  - b. partial nephrectomy is not feasible after 12 weeks of chemotherapy.

A generous transabdominal, transperitoneal or thoracoabdominal incision is recommended for adequate exposure. Complete exploration of the abdomen should be performed. To expose the primary tumor the lateral peritoneal reflection is then opened, and the colon is reflected medially. A radical nephrectomy is performed with the dissection plane established outside of Gerota's fascia. Before mobilizing the primary tumor, an attempt should be made to dissect, expose and ligate the renal vessels in order to lessen the chance of hematogenous spread of tumor cells while removing the tumor. **Preliminary ligation should not be pursued if technically difficult or dangerous.** The adrenal gland may be left in place if it is not abutting the tumor; but, if the mass arises in the upper pole of the kidney, the adrenal gland should be removed with the neoplasm. The ureter is ligated and divided as low as conveniently possible but it is not necessary to remove the entire ureter. The tumor and the uninvolved portion of the kidney are mobilized and removed intact. Any enlarged or suspicious lymph nodes should be included with the specimen.

The use of titanium clips is strongly recommended to identify gross residual tumor. Clips should not be used for hemostasis and those placed for roentgenographic identification or radiation therapy portals should be limited to the minimum number necessary. Metallic clips can interfere with the CT scan. Clips are best applied by placing a non-absorbable suture in the structure to be marked, and attaching the clip to the suture. In general, four small clips should be sufficient to delineate the margins of the tumor.

Any suspicious area that could represent metastases should be biopsied, the site(s) identified with small titanium clips so that the locations can be determined later by roentgenograms. The involved areas should be drawn on the diagram in the surgical checklist. The specimen should be specifically identified as to the site from which it was removed.