



Handbook for Children with Neuroblastoma

Updated Spring 2018

from the
Cancer Committee
of the
American Pediatric Surgical Association

CONTRIBUTORS

Mary Beth Madonna, MD
Associate Professor
Northwestern University Feinberg School of Medicine
Ann and Robert H Lurie Children's Hospital of Chicago
Chicago, IL
mmadonna@luriechildrens.org

Erika Newman, MD
Assistant Professor
University of Michigan
CS Mott Children's Hospital
Ann Arbor, MI
eaneuman@med.umich.edu

NOTICE

The authors, editors, and APSA disclaim any liability, loss, injury or damage incurred as a consequence, directly or indirectly, of the use or application of any of the contents of this volume. While authors and editors have made every effort to create guidelines that should be helpful, it is impossible to create a text that covers every clinical situation that may arise in regards to either diagnosis and/or treatment. Authors and editors cannot be held responsible for any typographic or other errors in the printing of this text. Any dosages or instructions in this text that are questioned should be cross referenced with other sources.

Attending physicians, residents, fellows, students and providers using this handbook in the treatment of pediatric patients should recognize that this text is not meant to be a replacement for discourse or consultations with the attending and consulting staff. Management strategies and styles discussed within this text are neither binding nor definitive and should not be treated as a collection of protocols.

TABLE OF CONTENTS

1. [Introduction](#)
2. [One-Minute Review](#)
3. [Staging](#)
4. [Risk Group Classification](#)
5. [Surgical Principles](#)

Introduction

This handbook provides you with current surgical management of neuroblastoma. It is based on current literature as well as accepted best practice, and is managed and updated by the APSA Cancer Committee. It is designed to consolidate the most current and up to date material you need to know when treating your patient. Neuroblastoma management is based on stage, age, imaging, and histologic and genomic characteristics.

This handbook begins with A One Minute Review, designed for use immediately before an operation, and includes abbreviated staging, risk stratification, surgery guidelines, and tissue handling. There follows more descriptive sections for staging, image defined risk factors, surgical management for biopsy and resection, special operative considerations, and management of surgical complications. Worth emphasis, there are two staging systems in use, the older and more familiar International Neuroblastoma Staging System Classification, (INSS) and the increasingly referenced International Neuroblastoma Risk Group Staging system (INRG) upon which new protocols are created, and is based upon Image Defined Risk groups. (IDRG). Moving forward the INSS classification system will be phased out and the INRG system will be the standard staging system for those treating patient with neuroblastoma.

Current research efforts in the Children's Oncology Group are focused on both de-escalation of therapy for non-high risk patients and intensification of therapy for high risk patients based upon histologic and genomic characteristics. Clinicians are strongly encouraged to consult with COG representatives, or the APSA COG surgeons listed below, for information on open COG studies for their patients with neuroblastoma.

Any and all suggestions for improvement are welcome.

APSA Pediatric Surgical Neuroblastoma Contacts:

Michael LaQuaglia (212) 639-7002 laquaglm@mskcc.org

Jed Nuchtern (832) 822-3135 nuchtern@bcm.tmc.edu

Mary Beth Madonna (312) 227-4210 mmadonna@luriechildrens.org

Erica Newman eanewman@med.umich.edu

ONE-MINUTE REVIEW

International Neuroblastoma Risk Group Staging System (INRGSS)

L1 Localized tumor, not involving vital structures as defined by the list of image-defined risk factors (IDRF); confined to one body compartment.

L2 Loco regional tumor with presence of one or more IDRFs

M Distant metastatic disease

Ms Metastatic disease in children younger than 18 months with metastases confined to skin, liver, and/or bone marrow (bone marrow involvement should be limited to < 10% of total nucleated cells on smears or biopsy).

INSS Staging

I Localized tumor, complete gross excision, LN negative.

IIA Localized tumor, gross residual disease, with either ipsilateral LN negative or LN sought/none found (w/specific mention in op note).

IIB Localized tumor, +/- gross residual disease, with either ipsilateral LN positive or no LN sought.

III Unresectable unilateral tumor +/- LN

Localized tumor with contralateral LN (+)

Midline tumor (If gross resection and LN (-) or LN sought/none found, then Stage I; if gross resection and no LN sought, then Stage 3)

IV Any primary tumor, metastases to distant LN, bone, bone marrow, liver, etc.

IV-S Localized, (I, IIA, IIB) metastases to skin, liver, and/or bone marrow, <1 year of age.

SURGICAL PRINCIPLES.

General Surgical Goals:

Establish diagnosis, accurate staging, most complete resection as safely possible-initial or after induction chemotherapy. Principles- Limit morbidity and mortality, resection of vital surrounding structures discouraged, control bleeding and avoid major hemorrhage, preserve normal organ function, avoid long delay in initiating chemotherapy in high-risk patients. Gross resection acceptable.

Specific Surgical Issues:

Primary Tumor-As near complete resection as possible, gross resection accepted. Avoid nephrectomy or other major organ removal and injury to surrounding vital structures.

Lymph Nodes –Grossly involved lymph nodes should be removed at the time of definitive tumor resection.. Regional Specific: Neck-along cervical chain, high and low neck; Thorax-upper, mid, and lower paraspinal, mediastinal, (6-9 nodes); Abdomen-paraaortic, bifurcation, paracaval, aortocaval, high at diaphragm, (6-9 LN total); Pelvis-paraaortic, paracaval, bifurcation, iliac chain, (6-9 LN total).

Other Liver biopsy if clinically suspicious.

Tissue Handling:

Fresh, tumor, > 1 gm (with bone marrow sample if possible) in sterile container with saline soaked gauze.

Observation Group:

Patients with INRG stage L1 tumors who are less than 12 months at diagnosis and have tumors < 5 cm in greatest diameter are currently being observed without biopsy, surgical resection or other treatment. These patients should be enrolled on the current COG non-high risk study, ANBL1232.

DETAILS OF NEUROBLASTOMA MANAGEMENT:

STAGING

INTERNATIONAL NEUROBLASTOMA RISK GROUP STAGING SYSTEM (INRGSS) AND IMAGE DEFINED RISK GROUPS

International Neuroblastoma Risk Group Staging System (INRGSS)

L1 Localized tumor, not involving vital structures as defined by the list of image-defined risk factors (IDRF), confined to one body compartment.

L2 Locoregional tumor with presence of one or more IDRFs

M Distant metastatic disease

Ms Metastatic disease in children younger than 18 months with metastases confined to skin, liver, and/or bone marrow (bone marrow involvement should be limited to < 10% of total nucleated cells on smears or biopsy).

IMAGE DEFINED RISK GROUP (IDRG) FACTORS—Current COG Definitions

Neck:

1. Tumor encasing carotid and/or vertebral artery and/or internal jugular vein
2. Tumor extending to base of skull
3. Tumor encasing or compressing the trachea

Cervico-thoracic junction:

1. Tumor encasing brachial plexus roots
2. Tumor encasing subclavian vessels and/or vertebral and/or carotid artery
3. Tumor encasing or compressing the trachea

Thorax:

1. Tumor encasing the aorta and/or major branches
2. Tumor encasing or compressing the trachea and/or principal bronchi

Thoraco-abdominal:

1. Tumor encasing the aorta and/or vena cava

Abdomen/pelvis:

1. Tumor infiltrating the porta hepatis and/or the hepatoduodenal ligament
2. Tumor encasing the branches of the superior mesenteric artery at the mesenteric root
3. Tumor encasing the origin of the celiac axis, and/or of the superior mesenteric artery
4. Tumor infiltrating or encasing one or both renal pedicles
5. Tumor encasing the aorta and/or vena cava
6. Tumor encasing the iliac vessels
7. Pelvic tumor crossing the sciatic notch

Risk factors related to symptoms and/or in situ tumor behavior AT ANY SITE-

1. Tumors with extension through the neural foramina at any level* WITH EITHER symptoms of spinal cord or nerve root compression OR abnormal spinal cord signal on imaging
2. Tumors with extension through the neural foramina at any level* WITH tumor invading >1/3rd of the spinal canal in the axial plane
3. Infiltration of adjacent organs/structures: pericardium, diaphragm, kidney, liver, duodeno-pancreatic block, and mesentery and others
4. Contiguous ipsilateral tumor extension across multiple body compartments (e.g., neck and chest, chest and abdomen, abdomen and pelvis)

NOTE: Ascites or pleural effusions, whether malignant cells are present or not, are NOT considered IDRFs. Therefore, effusions in the body cavity of a local-regional tumor do not impact the INRGSS stage. However, a malignant effusion in a distant body cavity, while not an IDRF, is considered metastatic disease so the INRGSS stage would be M.

Multifocal primary tumors are not considered image-defined risk factors.

Definitions used in designating IDRFs:

***Encasement** is present when tumor surrounds a structure with >50% circumferential contact; or when a vein is completely flattened by tumor with no visible lumen.*

***Infiltration** is present when a tumor extends into or deviates a vital structure and the margin between tumor and structure on imaging is absent or ill-defined.*

***Compression** refers only to airways and requires a narrowing of the airway due to tumor effects (airway deviation without compression is not an IDRF).*

INTERNATIONAL NEUROBLASTOMA STAGING SYSTEM (INSS) No longer used in COG protocols

Stage 1

Localized tumor with complete gross excision, with or without microscopic residual disease; representative ipsilateral lymph nodes negative for tumor microscopically (nodes attached to and removed with the primary tumor may be positive).

Stage 2A

Localized tumor with incomplete gross resection; representative ipsilateral nonadherent lymph nodes negative for tumor microscopically.

Stage 2B

Localized tumor with or without complete gross excision, with ipsilateral nonadherent lymph nodes positive for tumor; enlarged contralateral lymph nodes must be negative microscopically.

Stage 3

Unresectable unilateral tumor infiltrating across the midline, with or without regional lymph node involvement; or localized unilateral tumor with contralateral regional lymph node involvement; or midline tumor with bilateral extension by infiltration (unresectable) or by lymph node involvement.

Stage 4

Any primary tumor with dissemination to distant lymph nodes, bone, bone marrow, liver, skin, and/or other organs (except as defined for Stage 4S).

Stage 4S

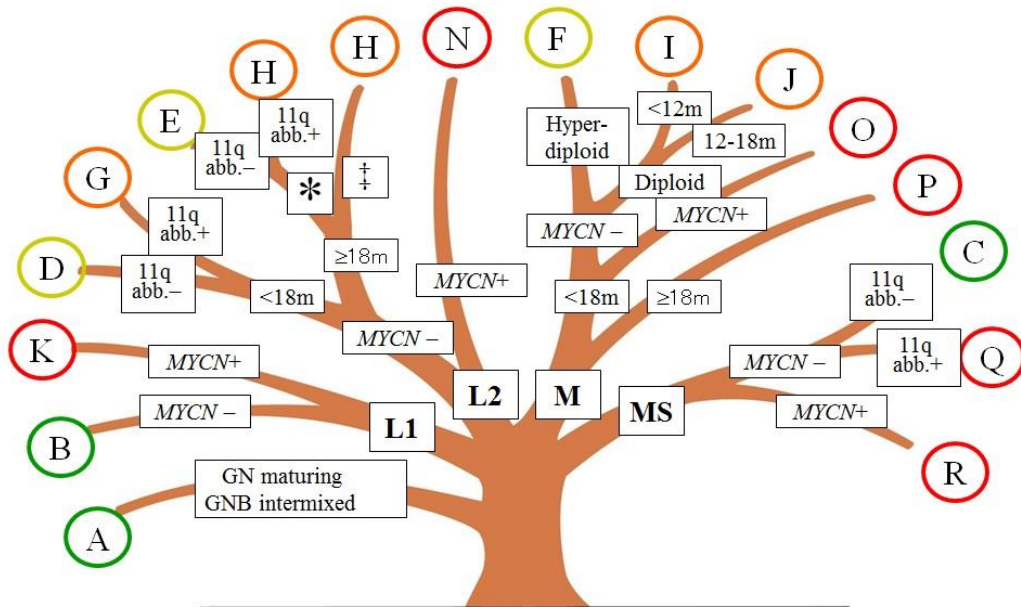
Localized primary tumor (as defined for Stage 1, 2A or 2B) with dissemination limited to skin, liver, and/or bone marrow³ (limited to infants <1 year of age).

1. Multifocal primary tumors (e.g., bilateral adrenal primary tumors) should be staged according to the greatest extent of disease, as defined above, and followed by a subscript “M” (e.g. 3M).
2. The midline is defined as the vertebral column. Tumors originating on one side and crossing the midline must infiltrate to or beyond the opposite side of the vertebral column.
3. Marrow involvement in Stage 4S should be minimal, i.e., less than 10% of total nucleated cells identified as malignant on bone marrow biopsy or marrow aspirate. More extensive marrow involvement would be considered to be Stage 4. The MIBG scan (if performed) should be negative in the marrow.
4. Proven malignant effusion within the thoracic cavity if it is bilateral, or the abdominal cavity, upstages the patient to INSS

RISK GROUP CLASSIFICATION

The INRG risk stratification system assigns patients into four overall risk groups: very low, low, intermediate, and high. Risk group assignment is based on age, INRG stage (L1, L2, M, Ms) and presence or absence of biological tumor characteristics including *MYCN* amplification, certain segmental chromosomal aberrations, and DNA ploidy. In addition, all ganglioneuromas (GN) are considered very low risk, as are ganglioneuroblastomas (GNB) with intermixed histology. The diagram below illustrates how these characteristics are used to for risk assignment in INRG. The table lists five-year event free survival and relative incidence for each risk group. Note: in COG, patients in pre-treatment group K (L1 tumor that is *MYCN* amplified) are not treated using high risk protocols but they are closely observed after resection.

The INRG Survival Tree



* NB or GNB nodular, differentiating ‡ NB or GNB nodular, poorly - or un-differentiated

Risk Group	Pre-treatment Group	Predicted 5-year EFS	Proportion of patients
Very low	A B C	>85%	28%
Low	D E F	76-85%	27%
Intermediate	G H I J	50-75%	9%
High	K N O P Q R	<50%	36%

SURGICAL PRINCIPLES

Primary Tumor

Resectability should be assessed by consideration of extension into adjacent structures, fixation to, or encasement of, major blood vessels, risk of hemorrhage, and the patient's overall tumor burden. Total resection of the primary tumor including the involved adrenal gland, sympathetic ganglia, or lymph nodes, but without removal of, or permanent damage to, other structures (spleen, kidney, bowel, major nerves and blood vessels) is the goal of this procedure, provided it would not result in significant delay in the initiation of chemotherapy, or associated with increased morbidity. This may necessitate leaving residual disease adherent to these anatomical structures. Nephrectomy should be avoided at initial exploration except for children who would be rendered entirely free of any residual disease. Liver biopsies for children are indicated if there is clinical or imaging suspicion of disease within the liver. Efforts should be made to biopsy the involved area. Titanium clips can be placed around sites of residual disease. Avoid metal clips in patients with thoracic primaries if possible. (artifact produced by these clips makes interpretation of CT scans for residual disease unreliable). A variety of incisions can be used for resection of the primary tumor. The choice of incision is based on surgeon preference and the best exposure of the lesion and important surrounding structures.

Initially unresectable tumors should have initial biopsy and central venous access placement. The goal of biopsy is to obtain enough tissue for a histopathological diagnosis as well as *MYCN* determination, cytogenetics, and other biological studies. The surgeon should try to obtain at least one to two cm³ of viable tumor tissue, if feasible, according to the surgeon's judgment. Core needle biopsies may be performed but there must be a sufficient number of cores that adequate tissue is obtained. For example, approximately 30-- 14 gauge cores are required to obtain sufficient tissue.

Delayed surgery for initial unresectable tumors should be performed with the goal of achieving the most complete tumor resection possible, consistent with preservation of full organ and neurologic function. Resection with microscopically negative margins may not be feasible because of proximity to major vascular structures and the spine. Instead, the surgeon should concentrate on removing, as completely as possible, all gross disease. Timing of delayed surgery is driven by overall treatment plan, generally considered after at least 2 cycles of induction chemotherapy, and with debate about benefit of delaying definitive operation beyond 4 cycles of chemotherapy.

Children with Ms disease require adequate biopsy of the primary or metastatic tumor for histology and biologic studies.

Infants with Ms disease who are less than 3 months of age are at particular risk for surgical complications if they have massive hepatomegaly with or without coagulopathy. In these patients, all attempts possible should be made to biopsy extra- abdominal sites of disease if they exist. These patients are often started on chemotherapy without biopsy and tumor biopsy is obtained when they are more stable (within one month of starting therapy). Percutaneous needle biopsies may not be sufficient for thorough histologic and genomic analysis depending on your institution interventional radiology expertise.

Cervical Primary Tumors

Pre-operative imaging studies directed to the primary tumor should include contrast enhanced computerized tomography extending from the lower skull to the thoracic inlet. Tumor extending into the mediastinum changes the surgical approach and should be appreciated

preoperatively. Magnetic resonance imaging is also a useful study. Encasement of the vertebral or carotid arteries, jugular vein, or extension across the midline or to the base of the skull are INRG image-defined high-risk factors and neoadjuvant chemotherapy is indicated.

All patients undergoing resection of a cervical or upper mediastinal primary will have a post-operative Horner's syndrome and this should be discussed with the family preoperatively. The exploration should be done through a transverse incision. Although a Horner's syndrome is inevitable, every attempt is made to preserve the vagus nerve, brachial plexus, and other major nerves. Intraoperative nerve stimulation is very useful and should be coordinated with the anesthesiologist so that muscle relaxants are avoided. Similarly, major blood vessels, including the jugular vein and carotid artery are preserved. If tumor is seriously adherent to these structures a partial removal should be done.

Thoracic Inlet Primaries

Imaging with either a contrast enhanced CT scan or MRI is crucial because of the very complicated anatomy in this region. Also, the need for resection should be carefully discussed among the treating services. Usually, this area cannot be adequately exposed without a cervico-thoracic ("trap door") incision. The vagus and phrenic nerves should be preserved at all costs as well as the great vessels. The surgeon should leave residual tumor if strongly adherent to any of these structures.

Mediastinal Primaries

Resection is usually performed through an open thoracotomy, but there are some reports of thoracoscopic exploration and resection. The recurrent, phrenic, and vagus nerves are at risk and should be avoided. Strong adherence to these nerves or blood vessels should prompt the surgeon to leave the adherent tumor rather than risk a neurovascular injury. The thoracic duct is easily injured, often in the region just posterior to the carina or near the right hemidiaphragm. The surgeon should pay special attention to this area and attempt to seal any visible lymphatics.

Abdominal Primaries

The goal is the most complete resection possible without putting organs at risk. Tumor masses encasing major visceral vessels that are not easily dissectible should be left in place. The major vessels include the celiac axis, superior mesenteric artery and vein, renal arteries and veins, and the inferior mesenteric artery. At no point should the surgeon risk kidney loss, or bowel infarction in resection of non-high risk abdominal neuroblastoma.

Pelvic Primaries

Tumors arising in the organ of Zuckerkandl or elsewhere in the pelvis are generally associated with excellent long-term survival, even when macroscopic disease is left in place. In addition, the morbidity of resection in this anatomic area is very high due in large part to injuries of the lumbosacral plexus or innervation to the bowel or bladder. Preoperative MRI is crucial to delineate the neural and sacral involvement. Preoperative anorectal manometry and urodynamic studies may be warranted to assess for occult sphincter dysfunction. A mechanical and antibiotic bowel preparation can be helpful. In most patients the best exposure is through a lower midline incision depending on the judgment of the operating surgeon. Dissection in the area of the aortic bifurcation and at the base of the inferior mesenteric artery should be avoided, if possible. The iliac arteries and veins should also be controlled early to avoid vascular injury. The surgeon should use nerve stimulation and consider neuro monitoring when operating near the pelvic sidewall. Often the obturator nerve can be visualized distally

near the obturator foramen and traced proximally to the area of the lumbosacral plexus. Incomplete resection should be considered to preserve major nerves or vascular structures.

Ms Tumors

The primary tumor in patients with Ms neuroblastoma should not be routinely resected. If necessary, an adequate amount of tissue may be obtained from biopsy of metastatic sites such as the liver or skin nodules. (adequate biologic information cannot be obtained from bone marrow alone in patients with Ms disease). If an operative biopsy is done, the surgeon should insure that an adequate amount of tissue (1-2 cm³) is removed and sent to the appropriate laboratories. For patients with stage Ms disease who are very ill and in whom an open biopsy to obtain tissue for diagnosis and biologic studies is considered medically contraindicated, every effort should be made to obtain some tumor tissue by needle aspiration of a metastatic site for at minimum the determination of *MYCN* and 1p/11q status. However, in these patients biopsy may be deferred for up to one month while patients are treated with chemotherapy and stabilized.

Epidural Tumors with Intraspinous Extension

When the tumor approaches the spinal canal on imaging, a detailed examination must assess neurological function. The format for the examination, a modification of the ASCIA scale should be used to document the degree of neurologic dysfunction at diagnosis and at subsequent time points during and post-therapy.

Laminectomy should not be performed in patients who are neurologically asymptomatic. If neurologic deterioration occurs during chemotherapy, neurosurgical evaluation should be sought and operative decompression strongly considered. Appropriate to the degree of neurological impairment, the treating physicians may decide that operative neurosurgical decompression is indicated under these circumstances. If feasible, the neurosurgeon should perform an osteoplastic laminotomy, with secure replacement of the laminae after decompression has been accomplished.

Assessment of neurological function will be performed prior to each cycle of chemotherapy for all patients with paraspinal tumors. Neurologic and orthopedic evaluations will be a routine part of off therapy follow-up for patients with paraspinal tumors, and will be performed at 6, 12, 24, and 36 months post therapy, and then annually thereafter. Orthopedic evaluation will include assessment of scoliosis and of extremity deformity by upright spine x-ray at these time points

Under the new INRGSS lymph node dissection is not required. However, abnormal appearing lymph nodes should be sampled. The site of these lymph nodes should be clearly identified in the operative report.

Management of Surgical Complications

Intraoperative complications are site-dependent. Major hemorrhage from either venous or arterial structures is of concern with more infiltrative tumors. The principles of vascular surgery, including proximal and distal control, pertain. Appropriate intraoperative vascular surgical consultation should be sought if necessary. Crucial vessels like the carotid, subclavian, hepatic, superior mesenteric or renal arteries should be repaired and flow restored even if bypass grafting is required. Nerve injuries may also be incurred and should be primarily repaired using magnification. Intraoperative consultation with vascular, neurosurgical or plastic surgical specialists could be considered if these complications occur.

Special Operative Techniques

Nerve stimulation

Nerve stimulation can be useful in detecting motor nerves in the brachial, or lumbo-sacral plexus. This requires cooperation from the anesthesiologist, as muscle relaxation must be allowed to wear off. Nerve stimulation, as well as neuro monitoring should always be used when dissection along the pelvic sidewall or in the neck or thoracic inlet.

Ultrasonic dissector-aspirators

Some authors have described the use of ultrasonic dissectors (CUSA) to debulk the interior of large tumors allowing an easier capsular dissection. The technique is useful for friable tumors but not those that are stroma rich. The surgeon should try to perform a generous incisional biopsy prior to ultrasonic dissection as it is difficult to capture the tumor specimen after it has been aspirated into the device.

Thoracoscopy

Video-assisted thoracoscopy can be used to remove small posterior mediastinal or thoracic inlet tumors provided there is no vascular encasement. One-lung ventilation may be helpful, as is low pressure carbon dioxide into the chest cavity.

Laparoscopy

Laparoscopic resection of small adrenal or pelvic primaries can be done. Extensive tumors or those with significant vascular encasement, or local regional nodal spread can be more completely resected using standard open approaches.

Radiofrequency Ablation, Cryosurgery

These techniques have significant drawbacks when applied to lesions in proximity to major vascular structures and should be avoided when treating neuroblastoma.

Central Line Placement

Patients will require central venous access both for treatment and potential stem cell transplantation or apheresis. It is usually feasible and efficient to place a vascular access device and obtain a bone marrow aspirate and biopsy during the initial anesthetic. The appropriate catheter should be placed from initiation of therapy. If stem cell transplantation is likely a double-lumen central line can be considered.